

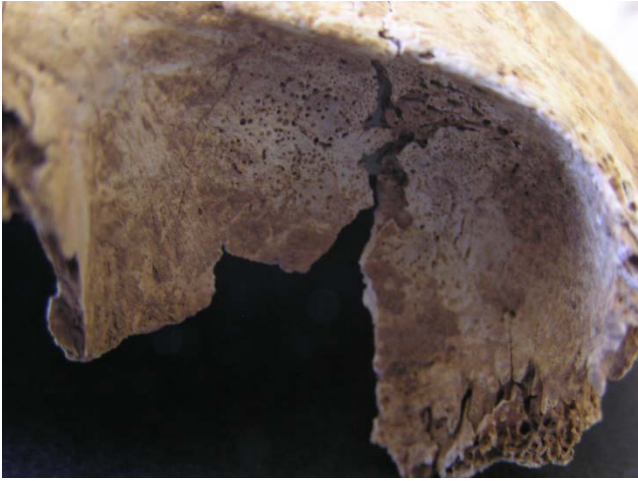

Fig. 25. Skel. 018. Cribra orbitalia




Fig. 26. Skel. 004. Porotic hyperostosis on cranial fragments



Fig. 27. Skel. 011. Endocranial lesions associated with scurvy



Fig. 28. Skel. 011. Ectocranial lesions associated with scurvy



Fig. 29. Skel. 011. Porotic lesions on the sphenoid bone associated with scurvy

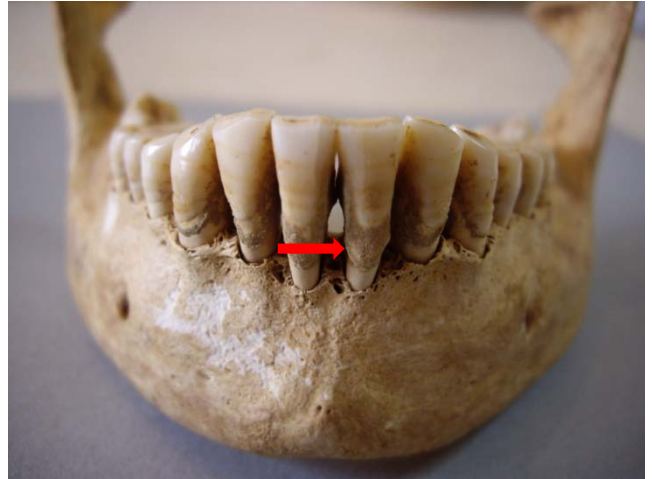


Fig. 30. Skel. 040. Calculus on mandibular teeth

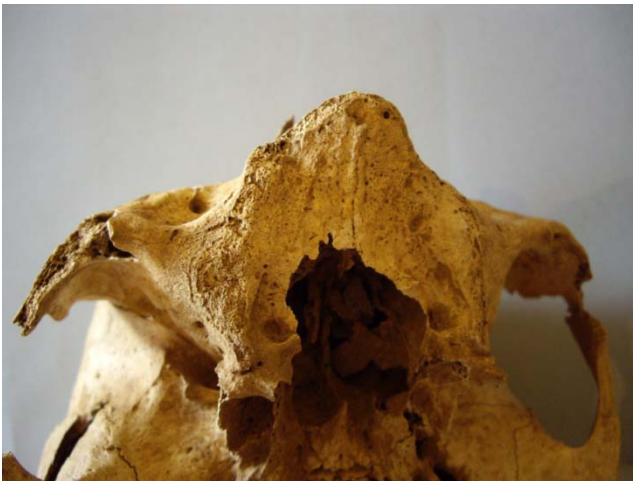

Fig. 31. Skel. 032b. Edentulous maxilla

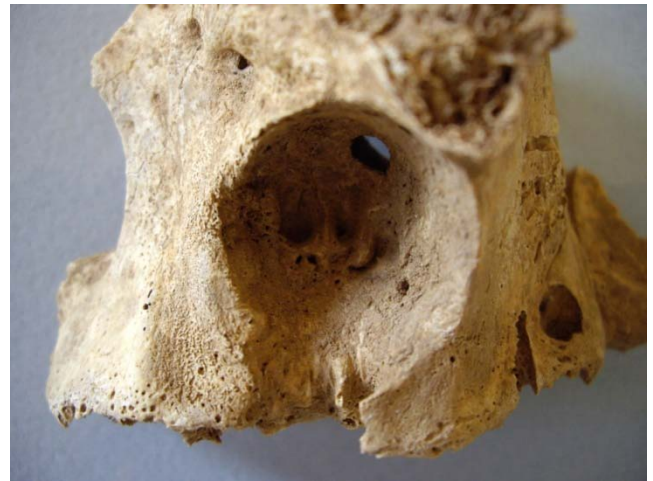

Fig. 32. Skel. 042. Massive destruction of the alveolar bone of the maxilla due to abscess



Fig. 33. Skel. 054. Osteoarthritis of cervical vertebrae



Fig. 34. Skel. 045. Ankylosis of sacrum and lumbar vertebrae

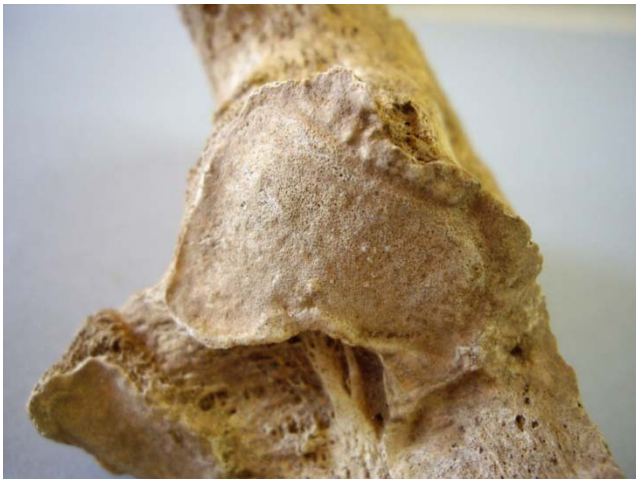

Fig. 35. Skel. 052. Osteoarthritis of tarsal bones



Fig. 36. Skel. 054. Discal prolapse on a lumbar vertebra



Fig. 37. Skel. 037. Schmorl' node on a lumbar vertebra

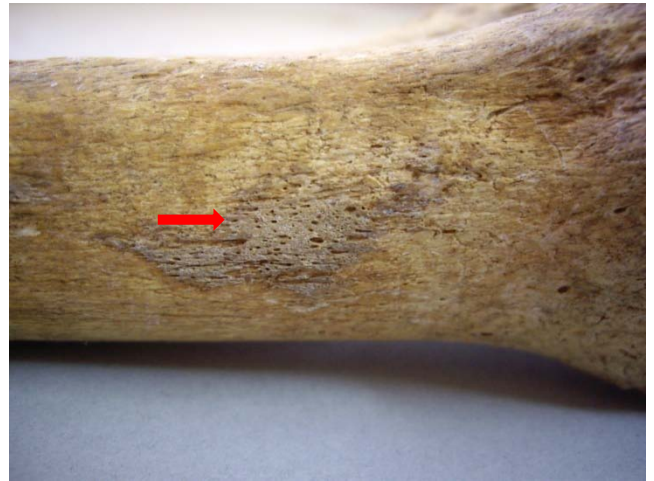

Fig. 38. Skel. 052. Periostitis on the distal tibia



Fig. 39. 37. Skel. 043. Parry fracture in distal ulna



Fig. 40. Skel. 045. Myositis ossificans on proximal femur



Fig. 41. Skel. 041. Cranial fracture



Fig. 42a, b. Skel. 040. Large perforation on the cranium (trepanation?)



Fig. 43. Skel. 051. Button osteomas on the cranium

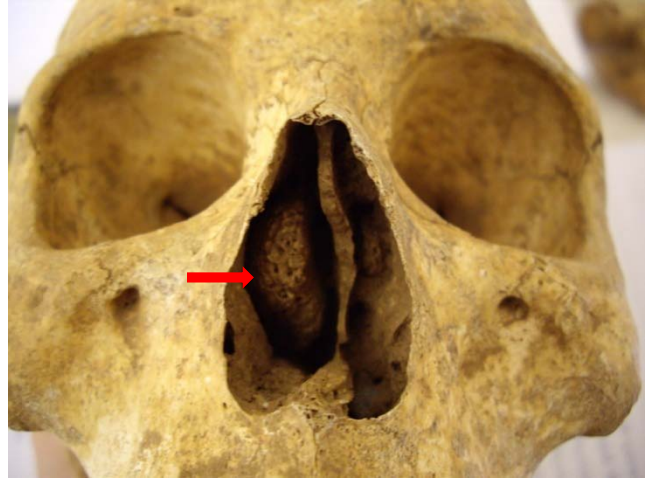

Fig. 44. Skel. 039. Osteoma of the ethmoid (?)